

口腔全攻略图谱

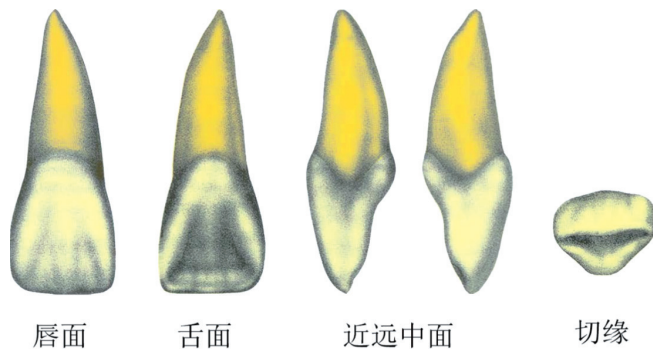


金英杰国家医学考试中心 编

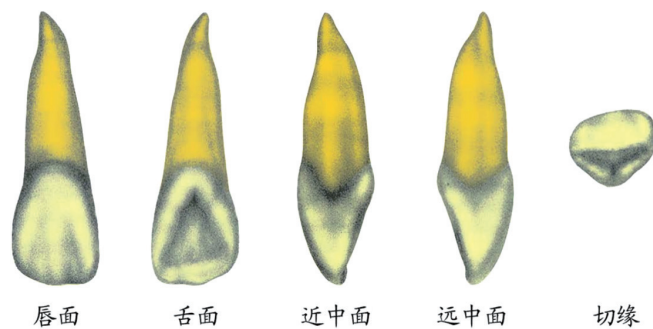
目 录

口腔解剖生理学.....	001
牙体牙髓病学、儿童口腔医学.....	026
牙周病学.....	034
口腔黏膜病学.....	041
口腔颌面外科学.....	048
口腔修复学.....	062
口腔颌面影像诊断学.....	076

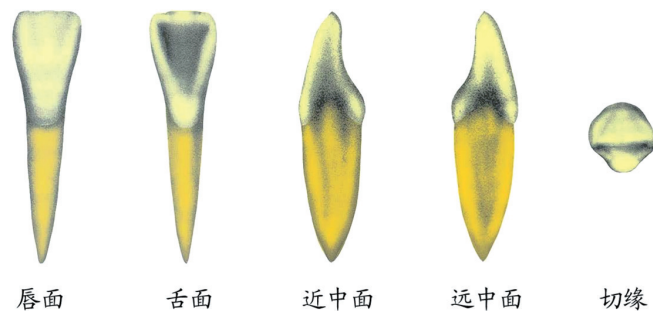
口腔解剖生理学



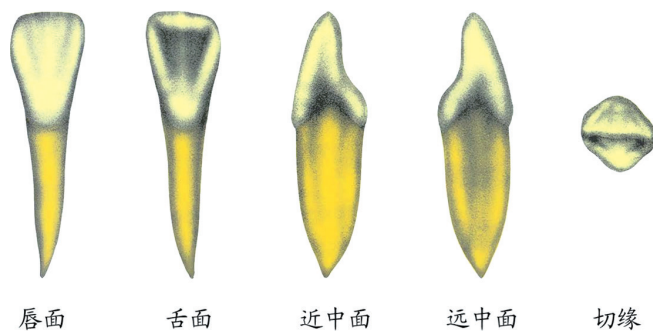
上颌中切牙



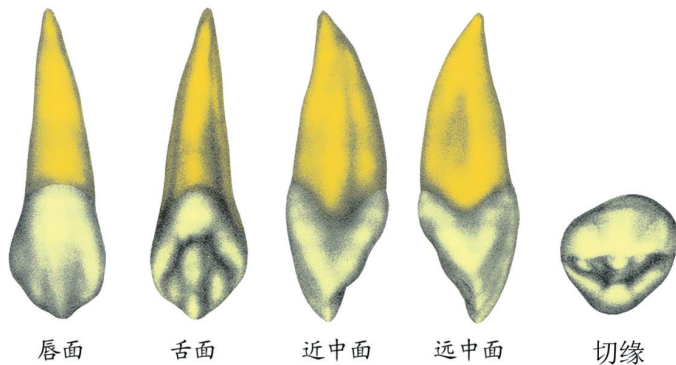
上颌侧切牙



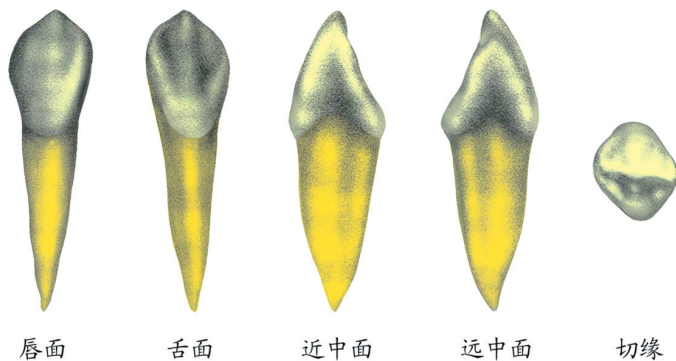
下颌中切牙



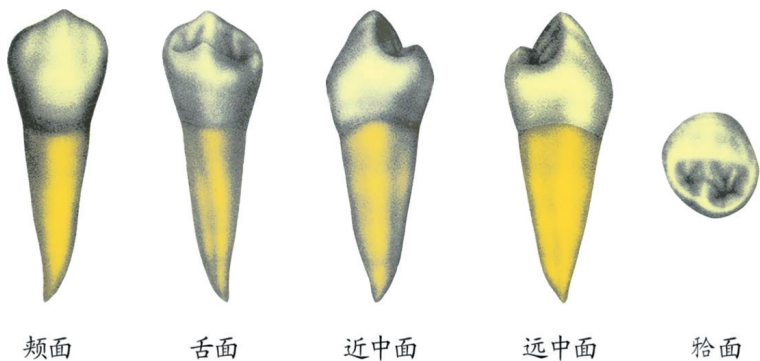
下颌侧切牙



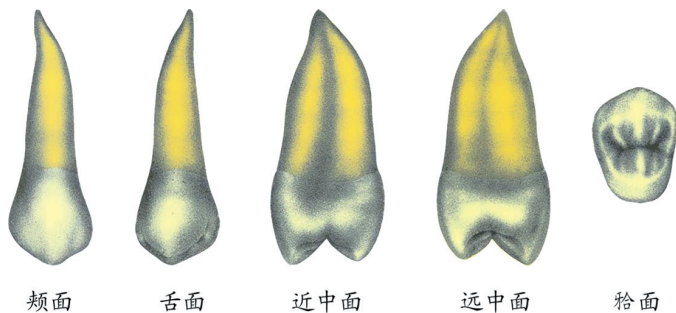
上颌尖牙



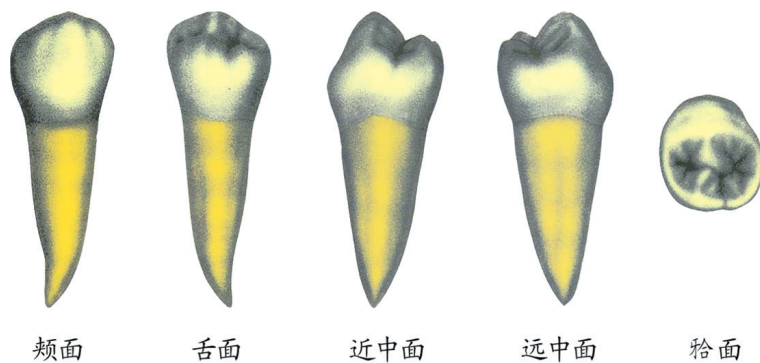
下颌尖牙



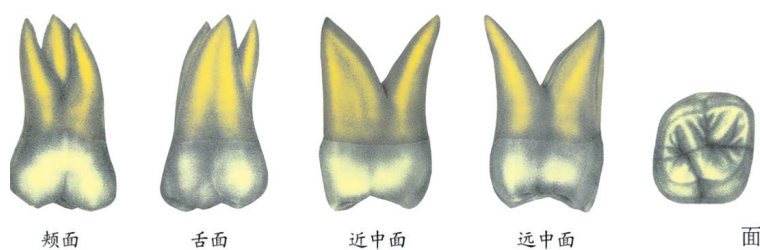
下颌第一前磨牙



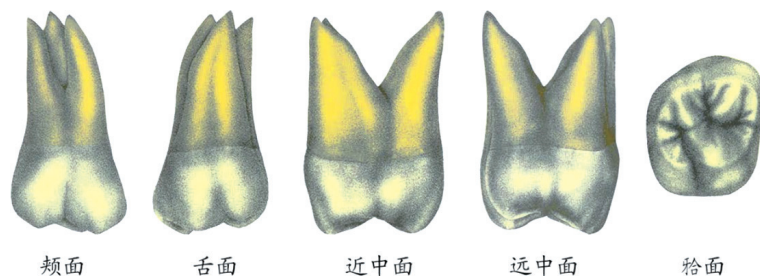
上颌第二前磨牙



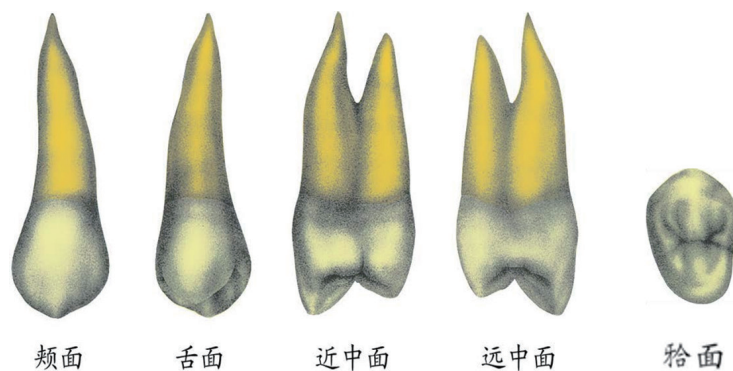
下颌第二前磨牙



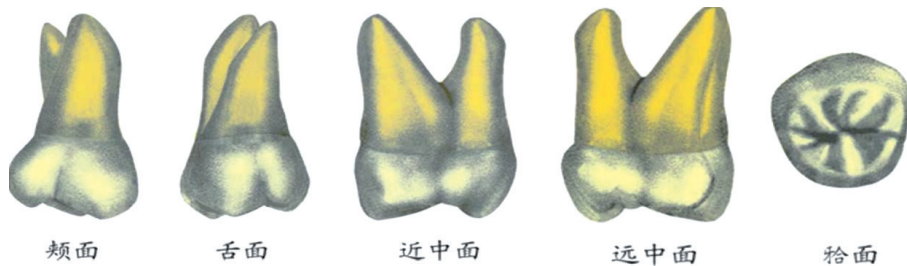
上颌第一磨牙



上颌第二磨牙



上颌第一前磨牙



颊面

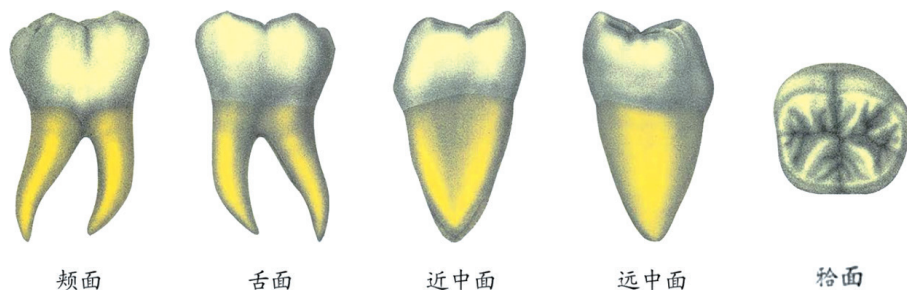
舌面

近中面

远中面

𪗗面

上颌第三磨牙



颊面

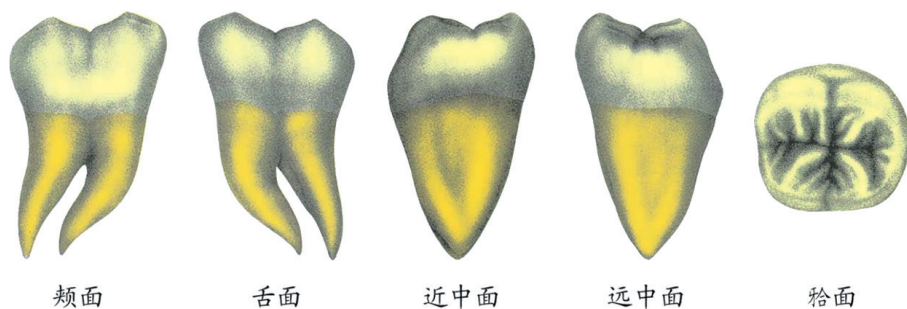
舌面

近中面

远中面

𪗗面

下颌第一磨牙



颊面

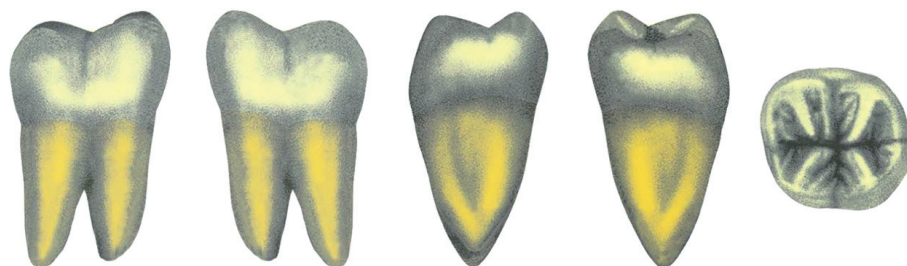舌面

近中面

远中面

𪗗面

下颌第二磨牙



颊面

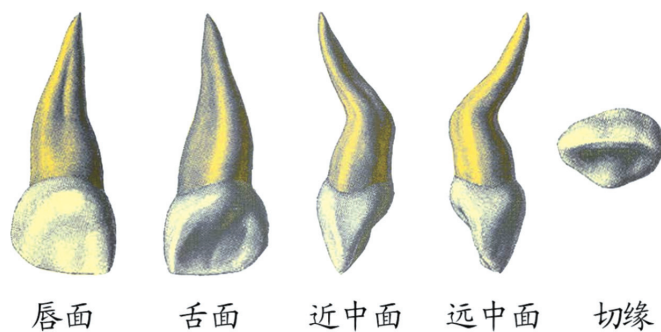
舌面

近中面

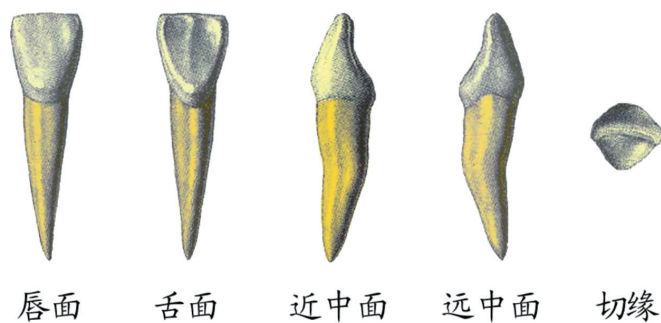
远中面

𪗗面

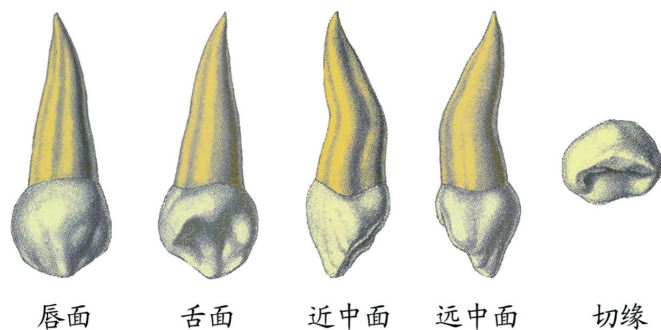
下颌第三磨牙



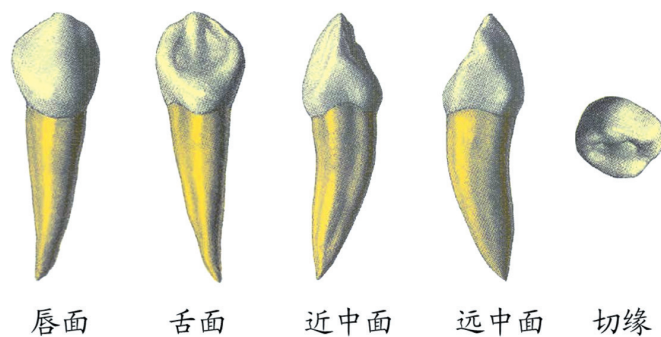
上颌乳中切牙



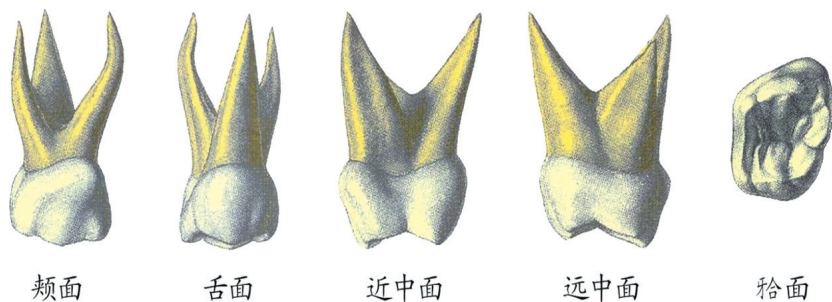
下颌乳中切牙



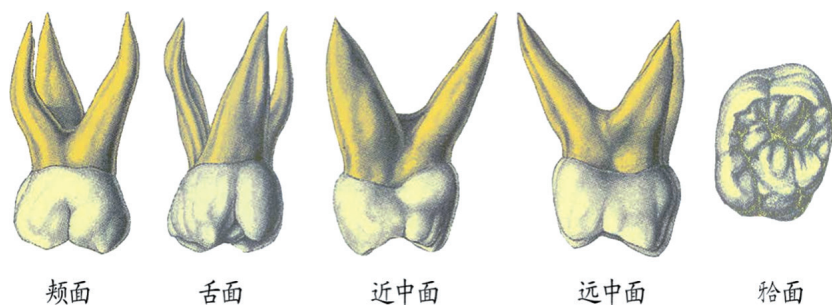
上颌乳尖牙



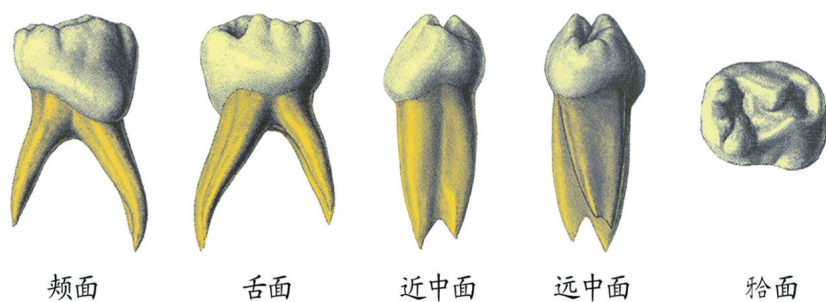
下颌乳尖牙



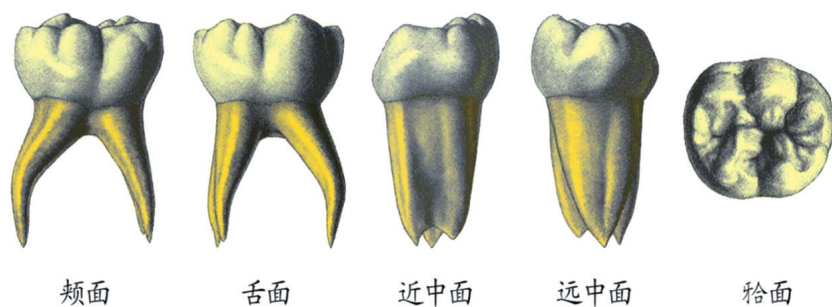
上颌第一乳磨牙



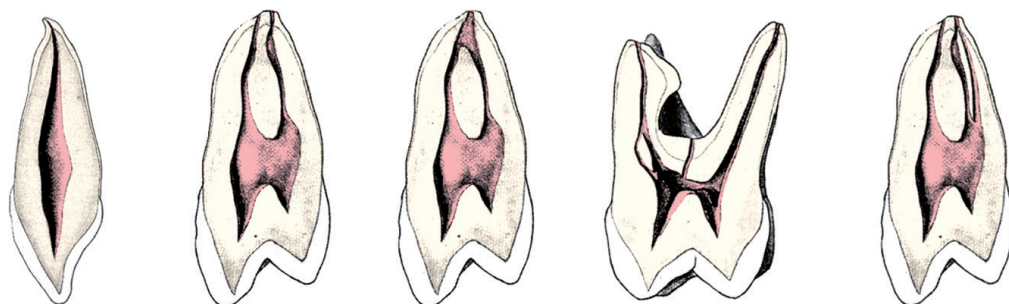
上颌第二乳磨牙



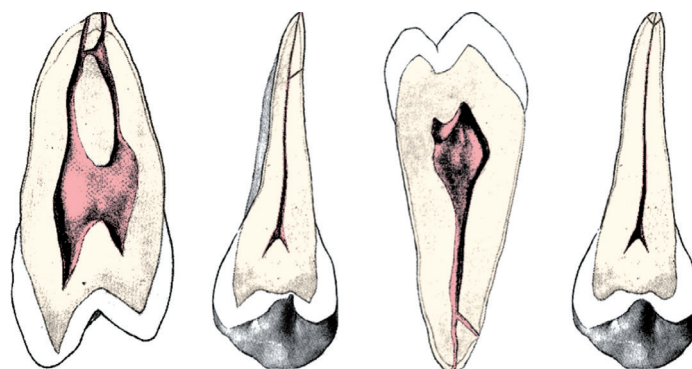
下颌第一乳磨牙



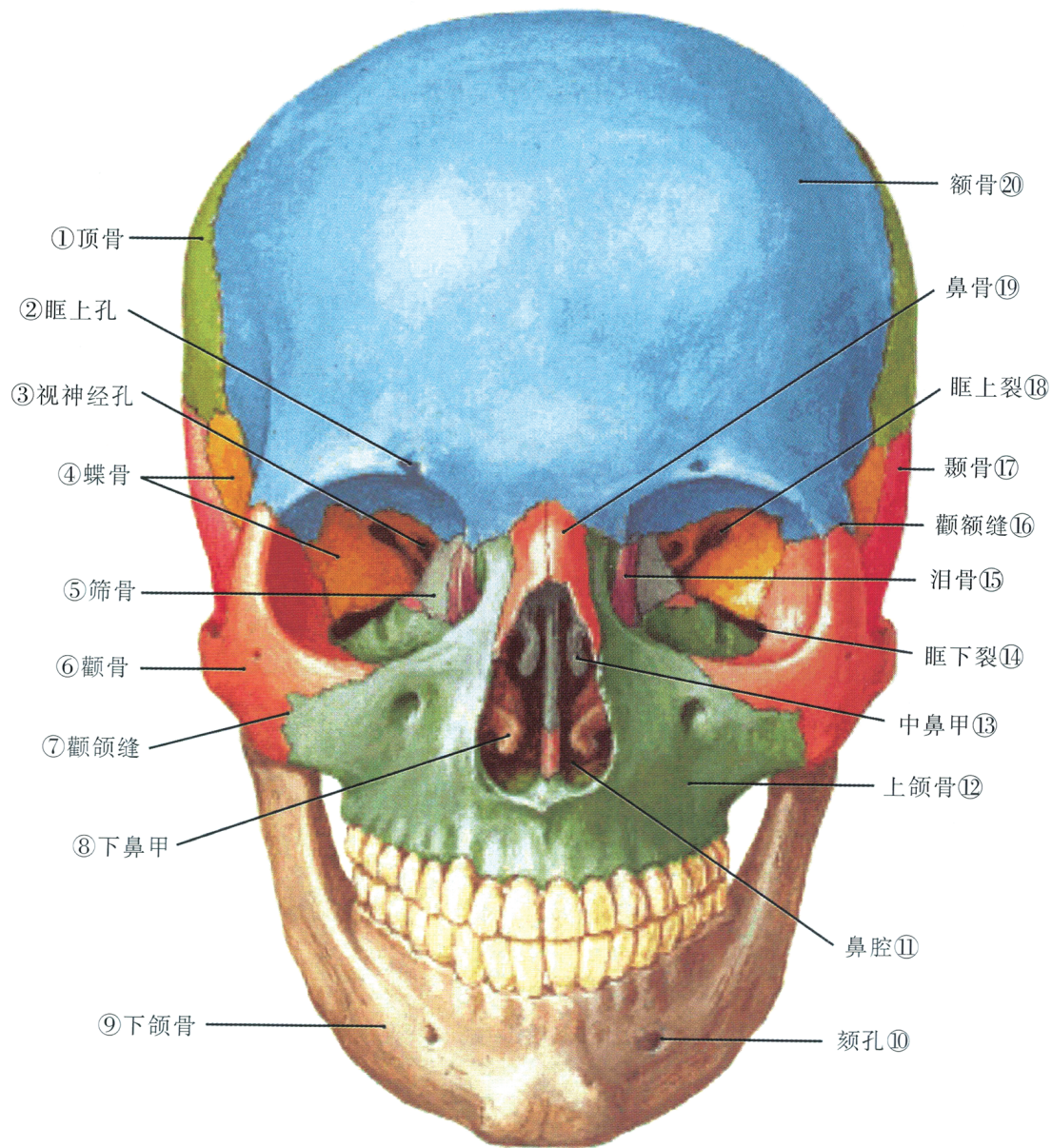
下颌第二乳磨牙



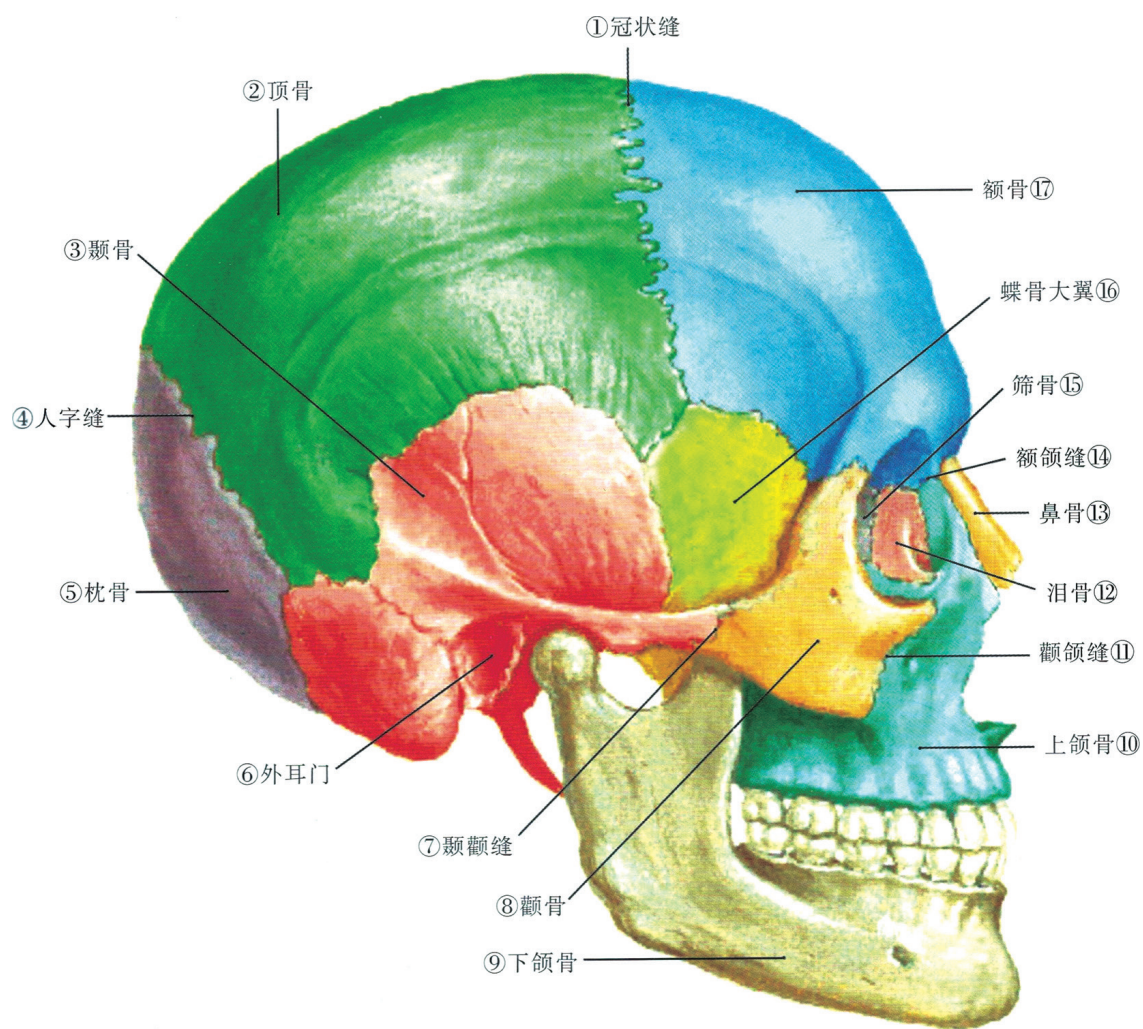
(1) (2) (3) (4) (5)
(1)单管型 (2)(3) 双管型 (4) 副根管及单双混合型 (5) 三管型



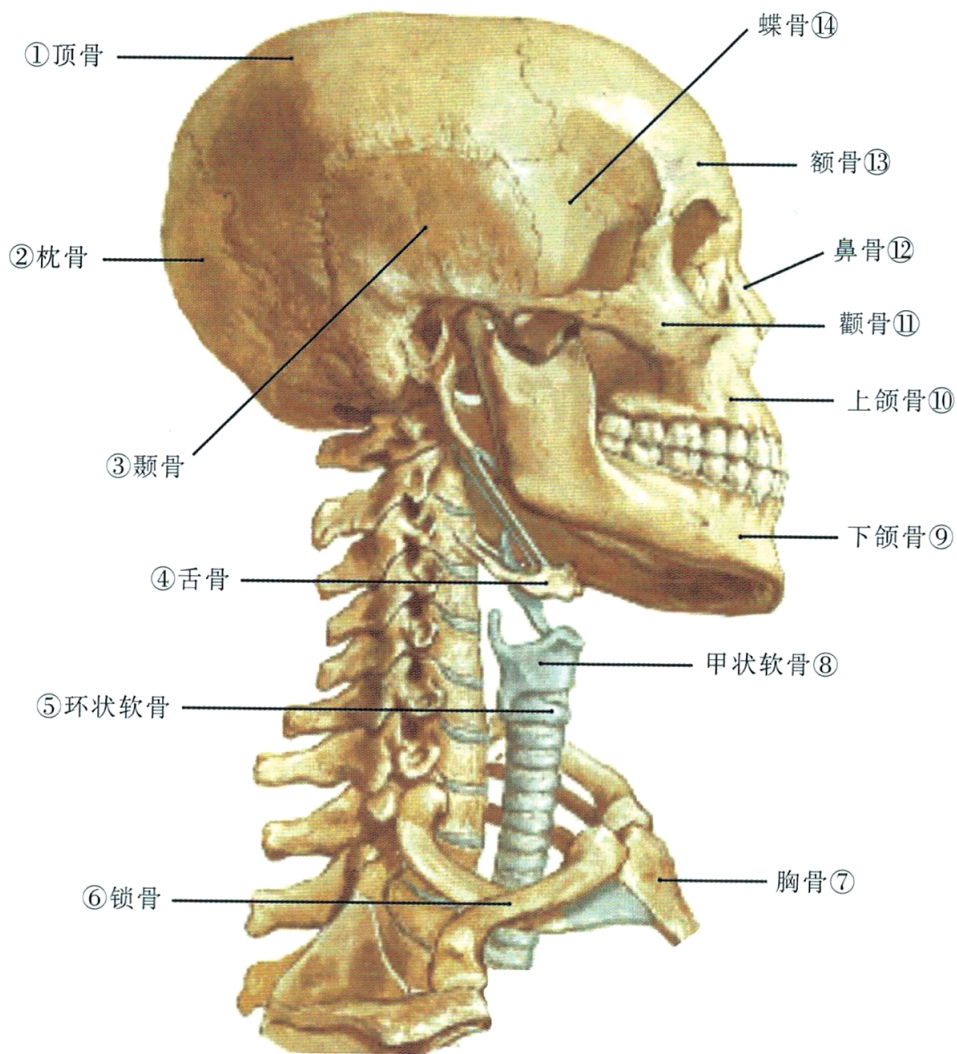
(1) (2) (3) (4)
(1) 管间侧支 (2)(3) 根管侧支 (4) 根尖分歧



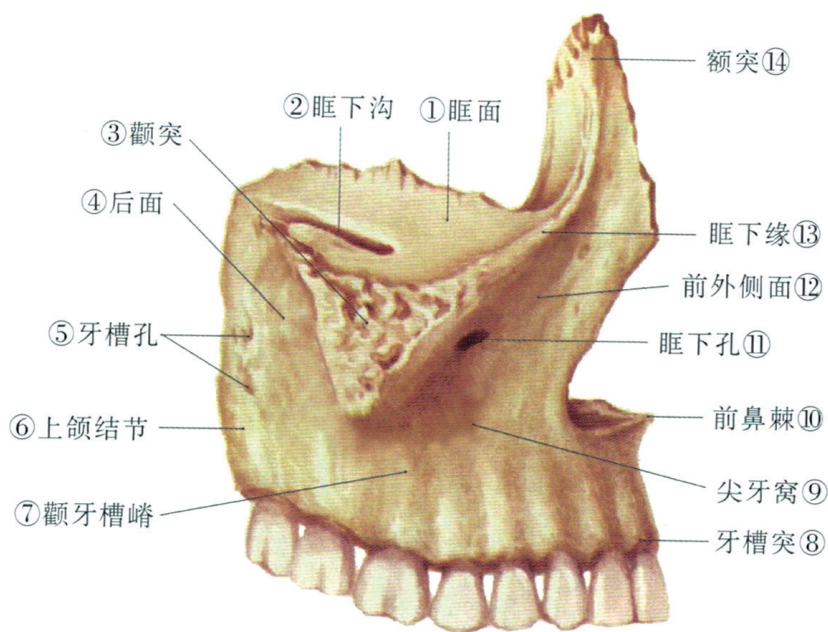
颅面骨骼前面观



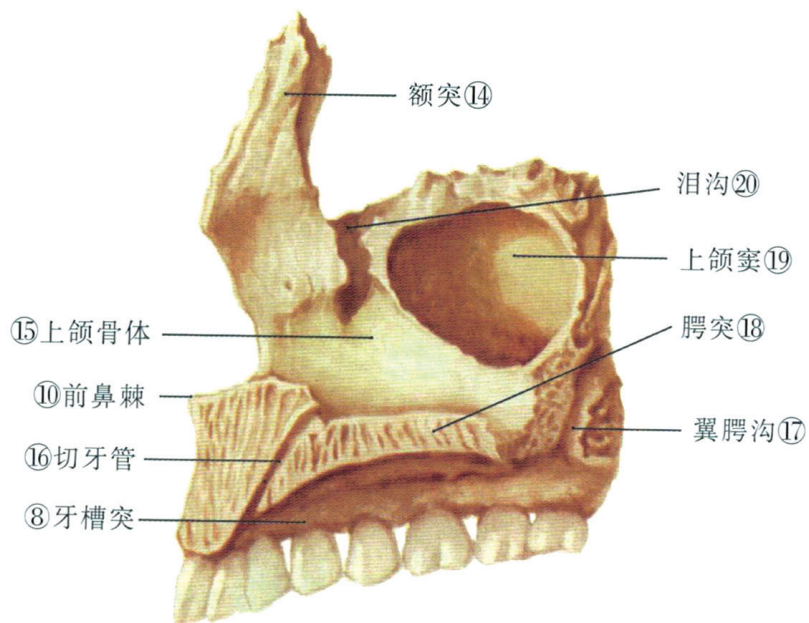
颅面骨骼外侧面观



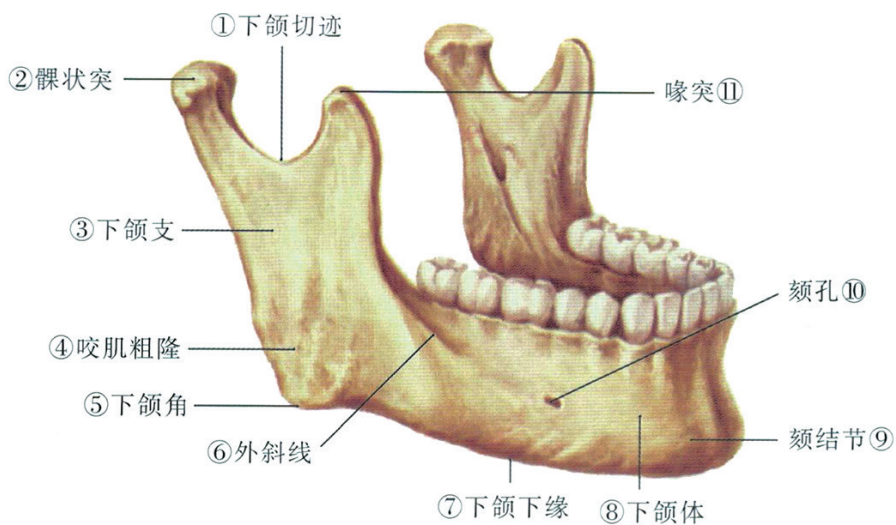
头颈部骨骼外侧面观



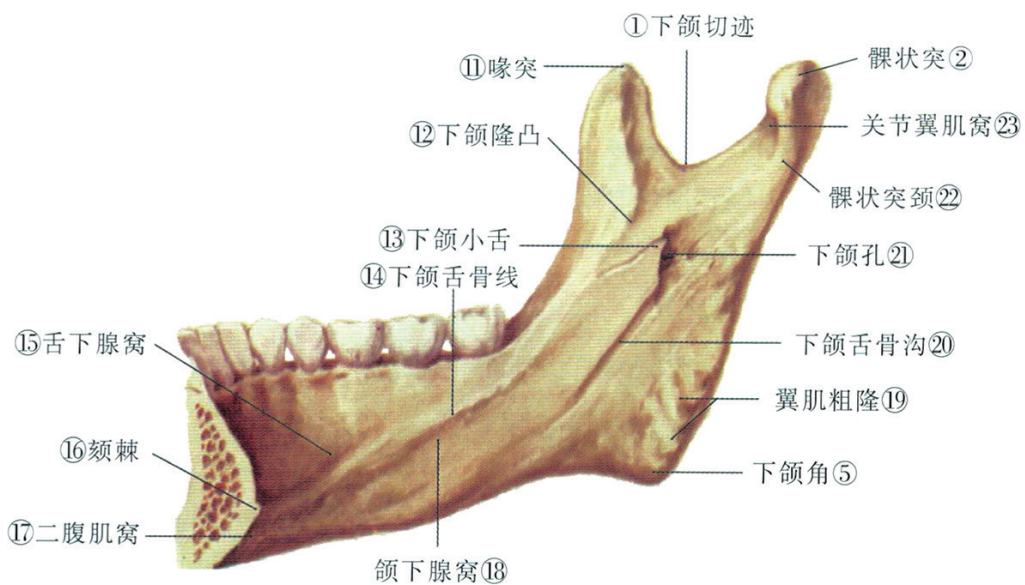
上颌骨外侧面观



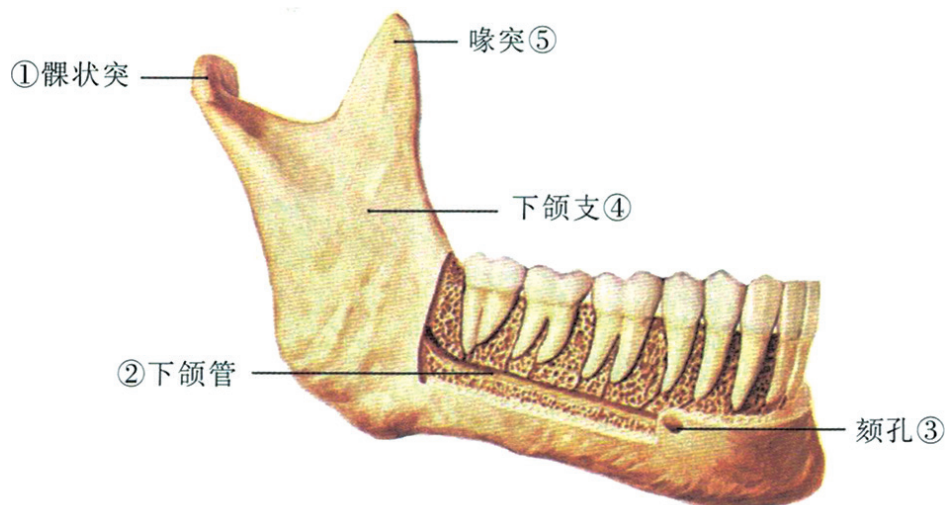
上颌骨内侧面观



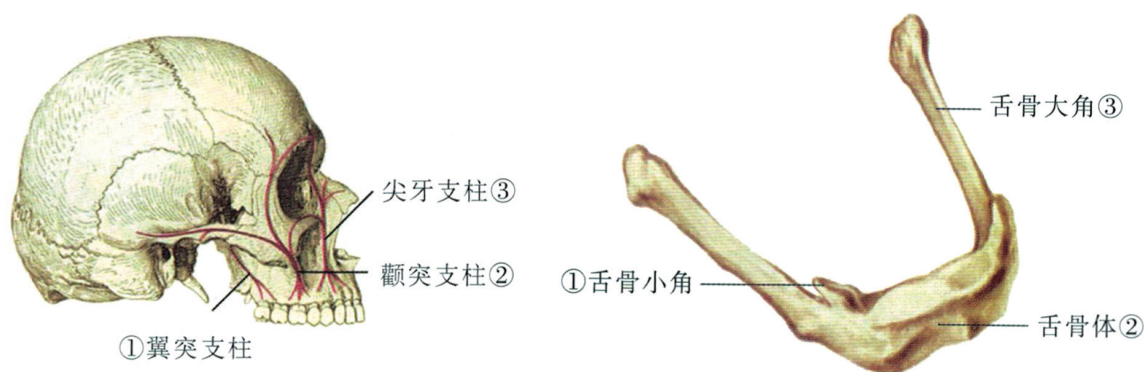
下颌骨外侧面观



下颌骨内侧面观

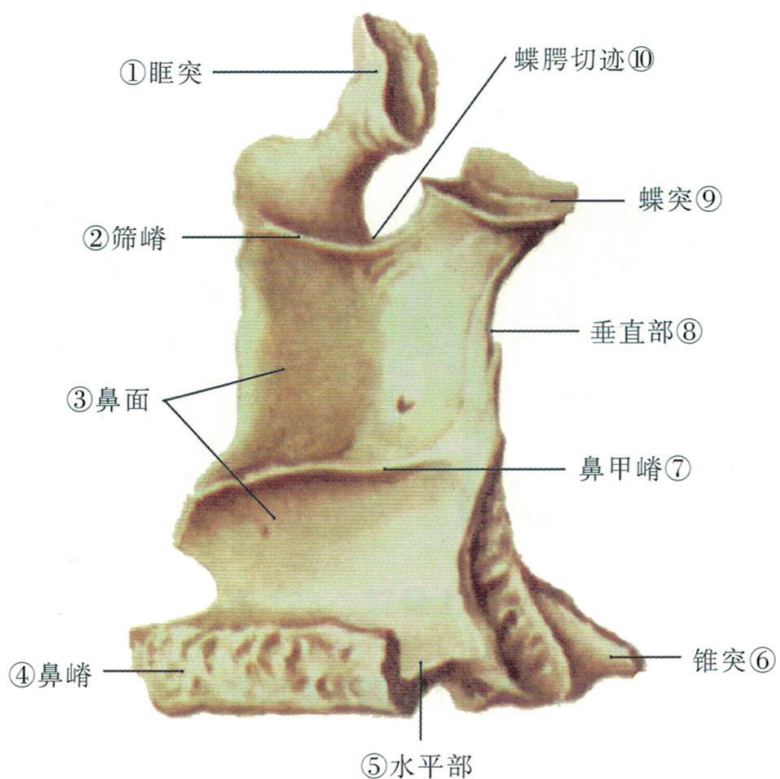


下颌管与下颌牙根的关系外侧面观

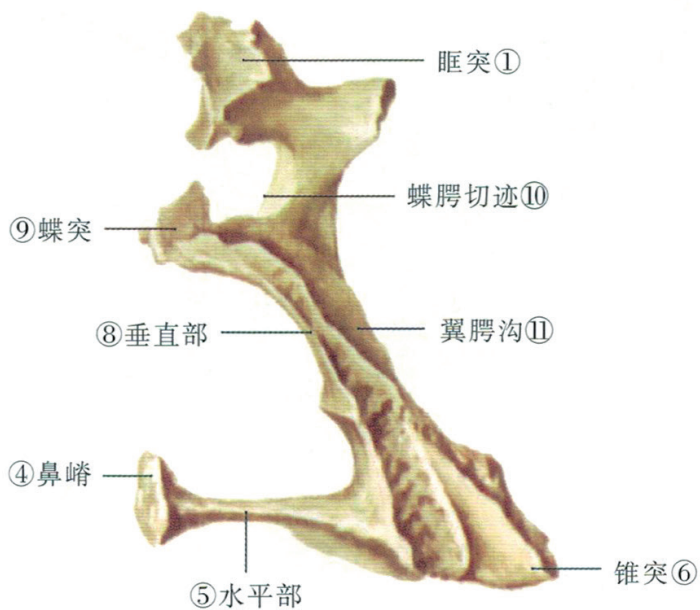


颌面骨的支柱结构外侧面观

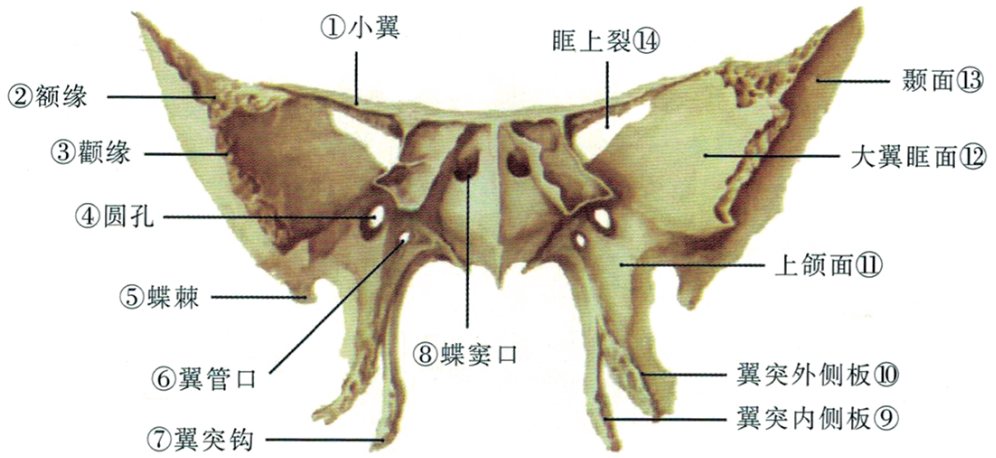
舌骨前外侧面观



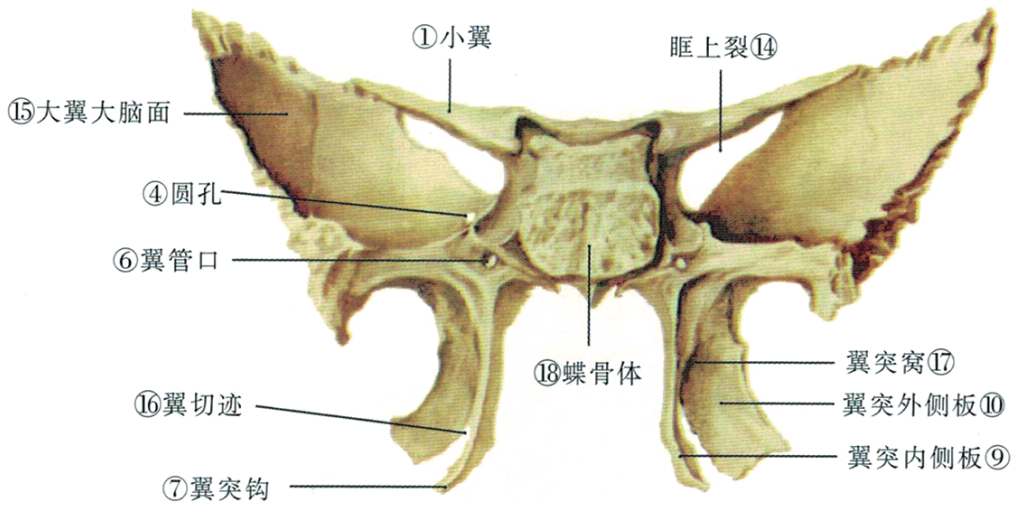
腭骨内侧面观



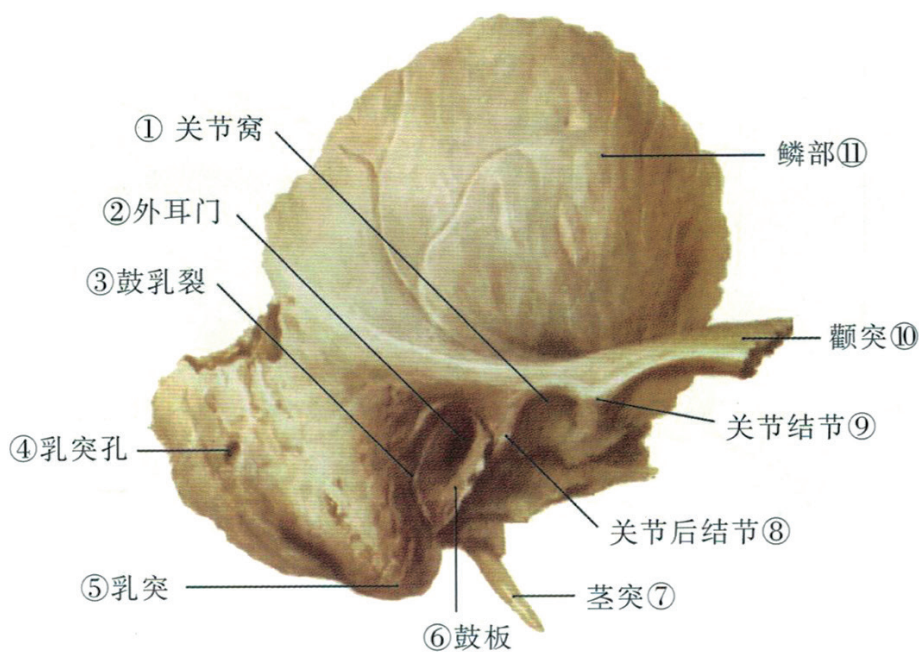
腭骨后面观



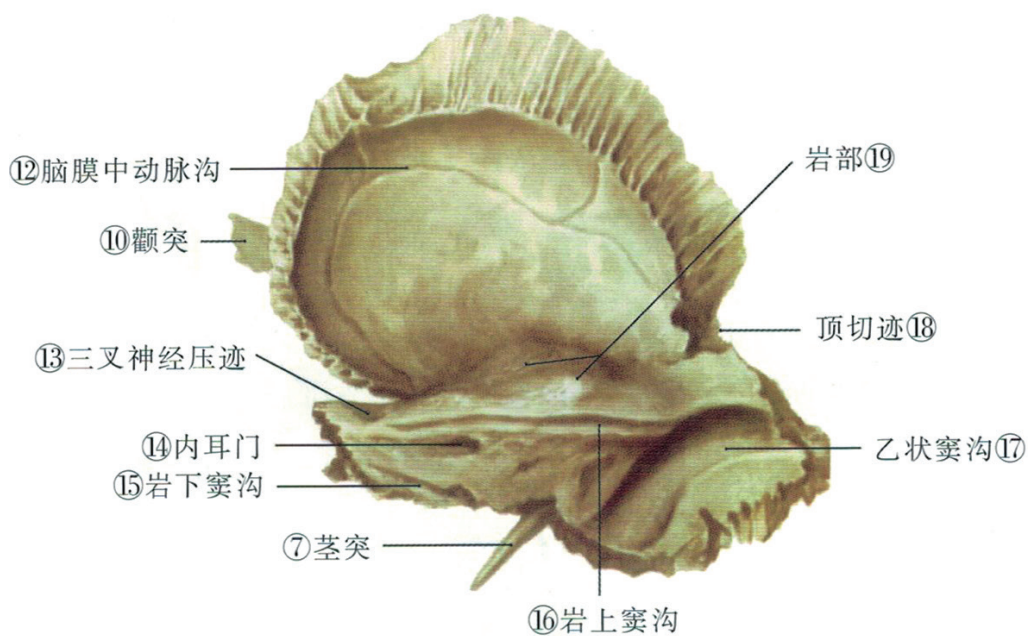
蝶骨前面观



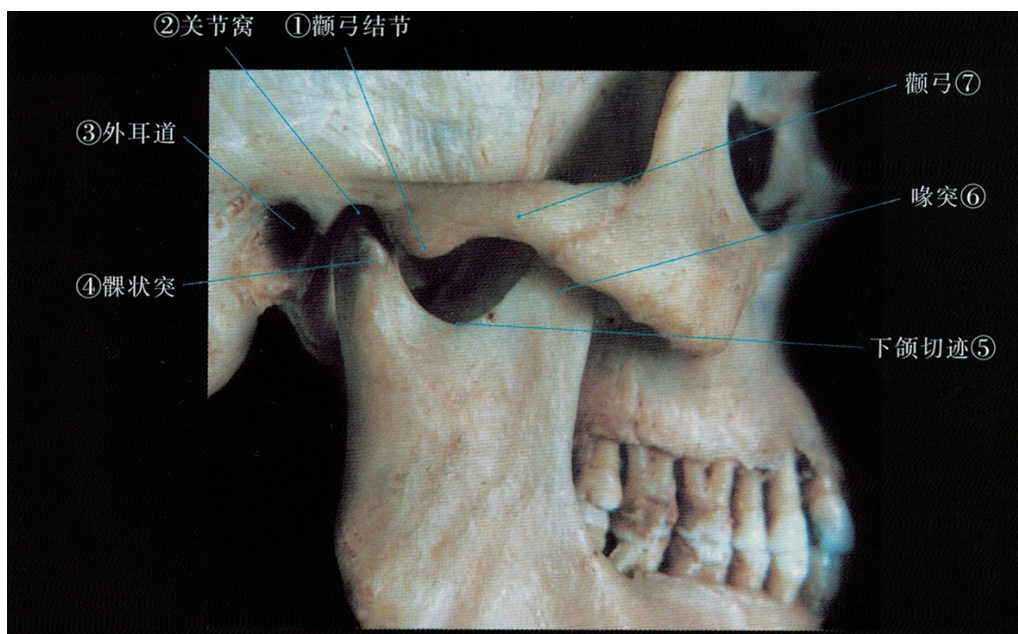
蝶骨后面观



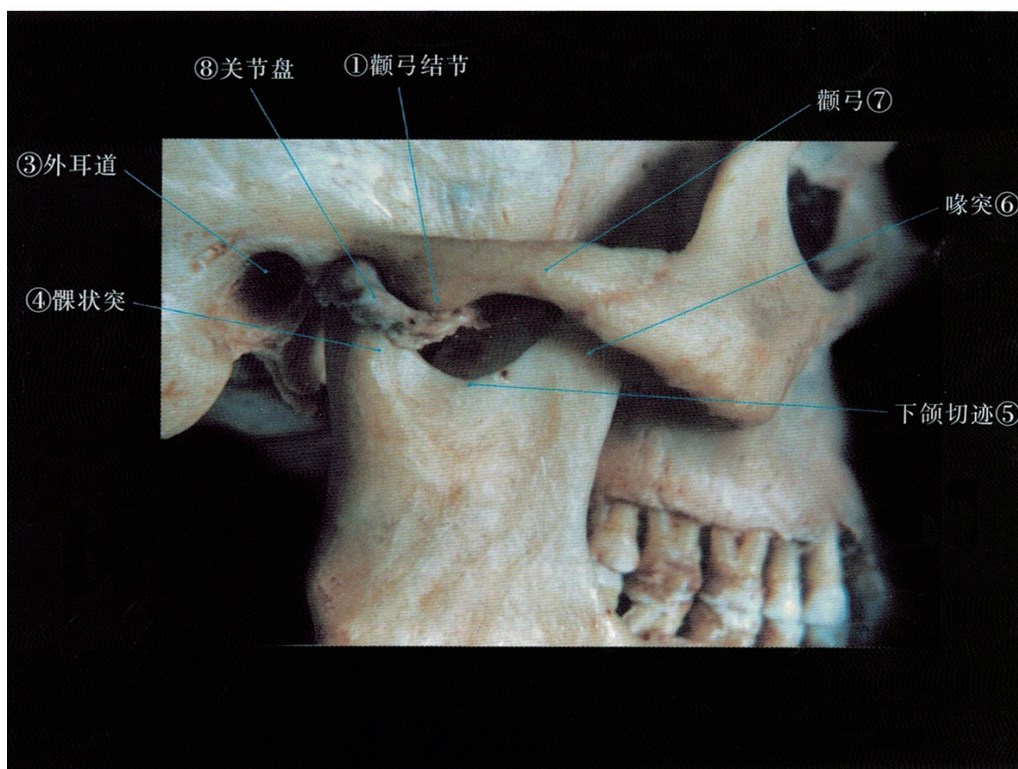颞骨外侧面观



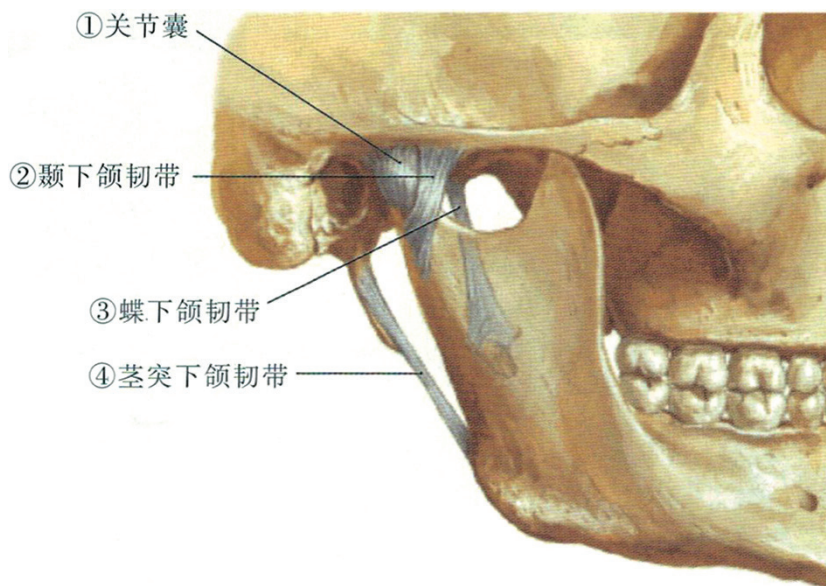
颞骨内侧面观



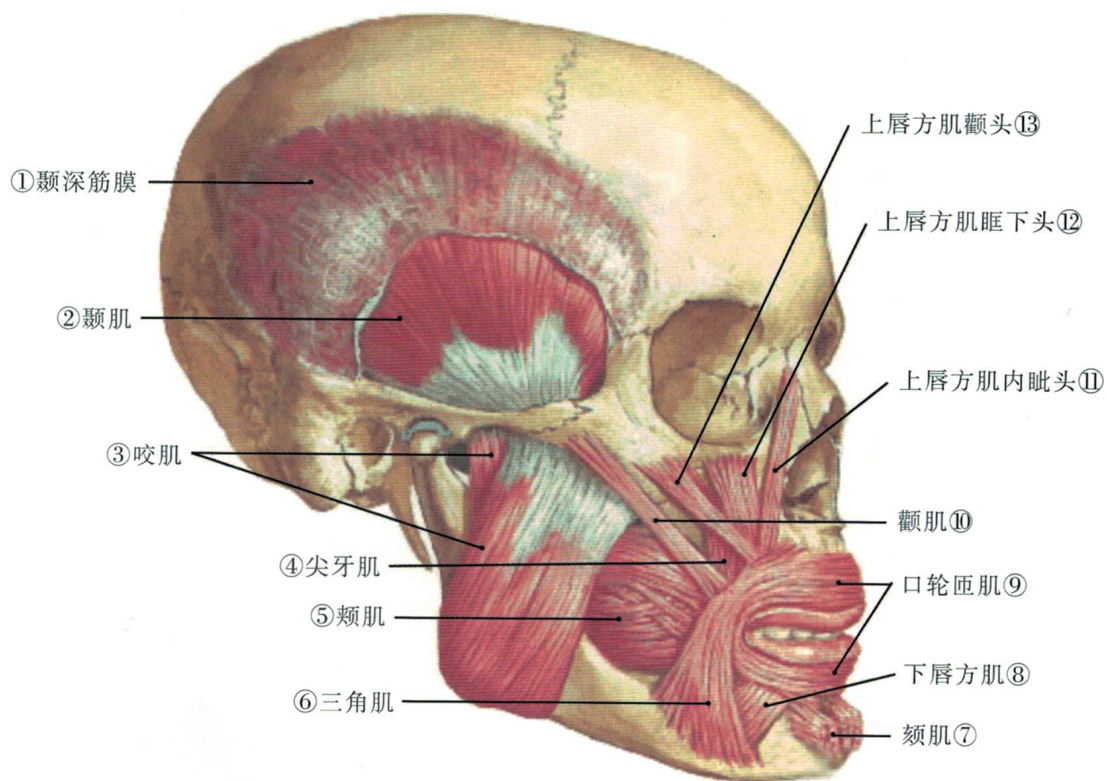
颞下颌关节骨性结构



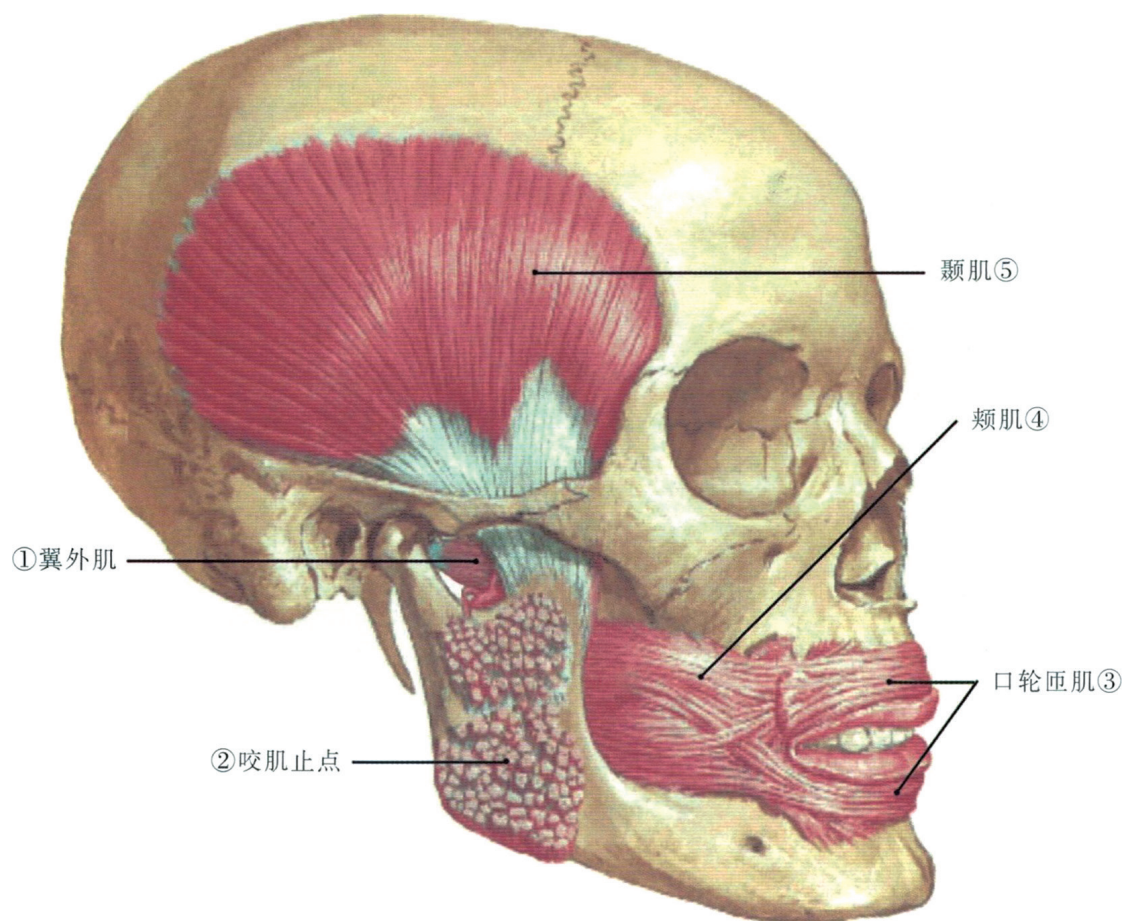
颞下颌关节结构关系



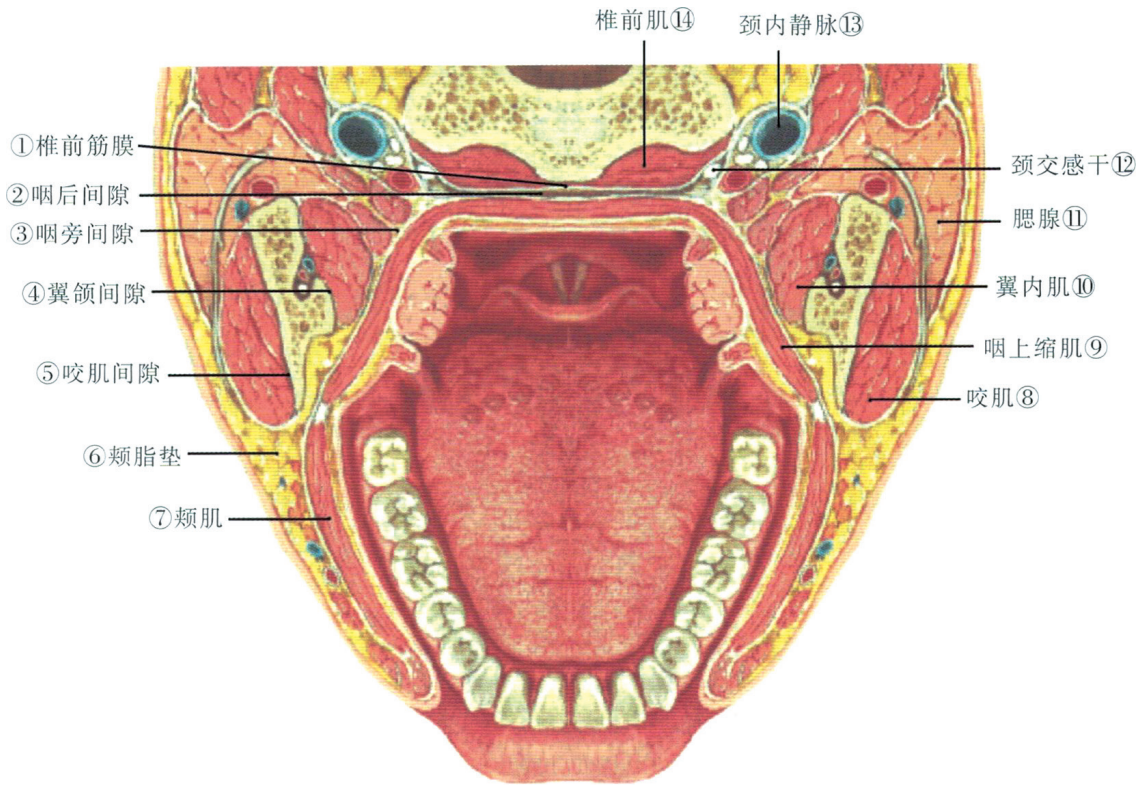
颞下颌关节外侧面观



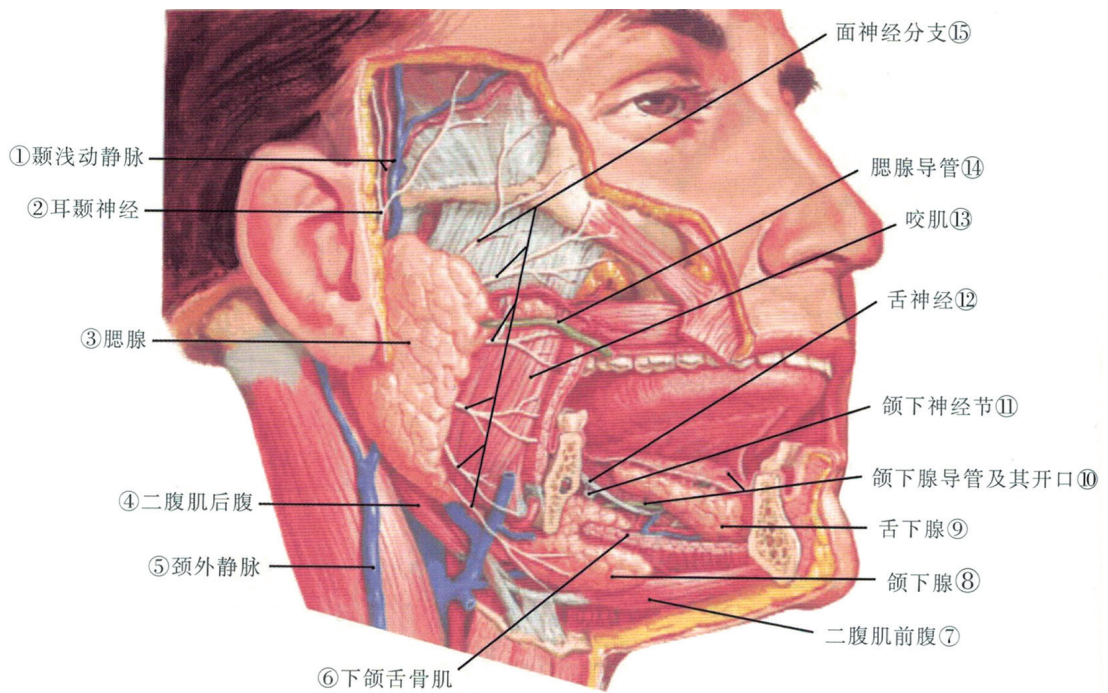
面部肌肉外侧面观



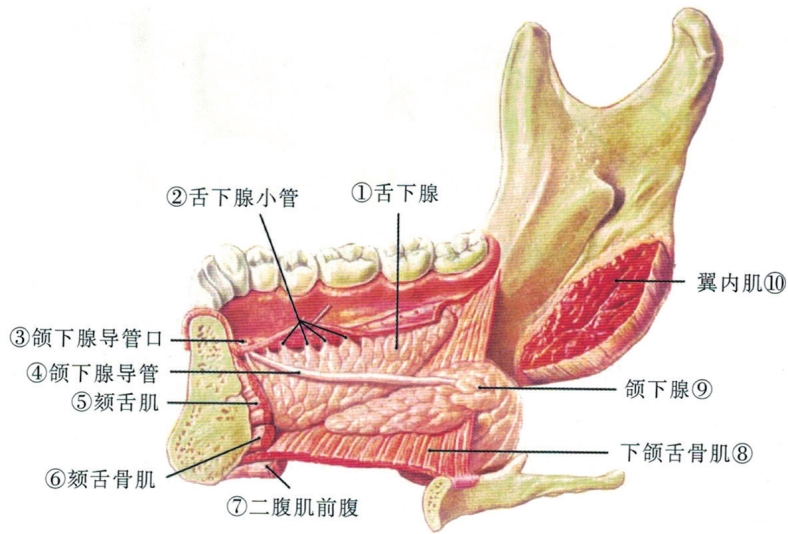
面部肌肉外侧面观



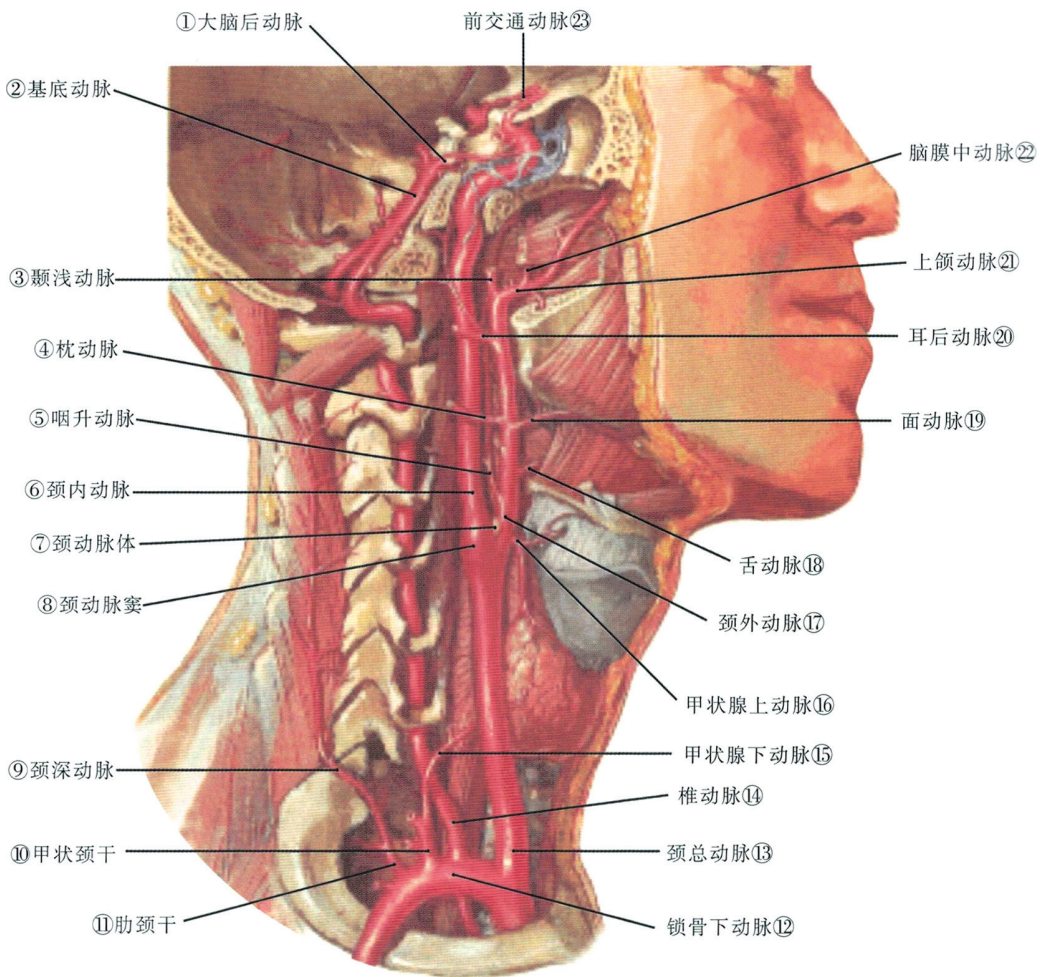
颌周蜂窝组织间隙水平切面观



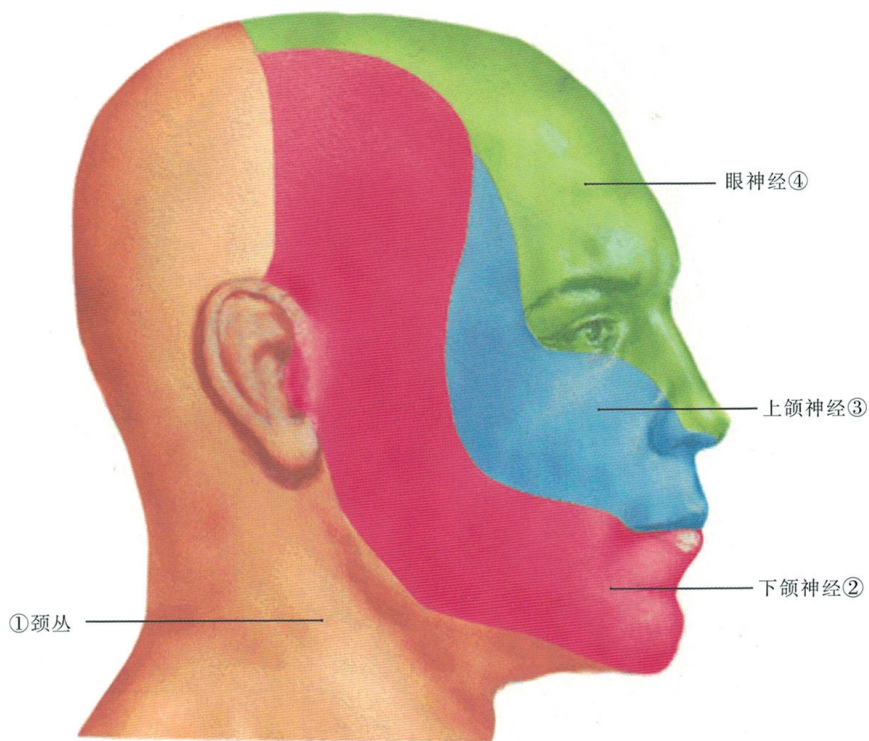
三大唾液腺外侧观



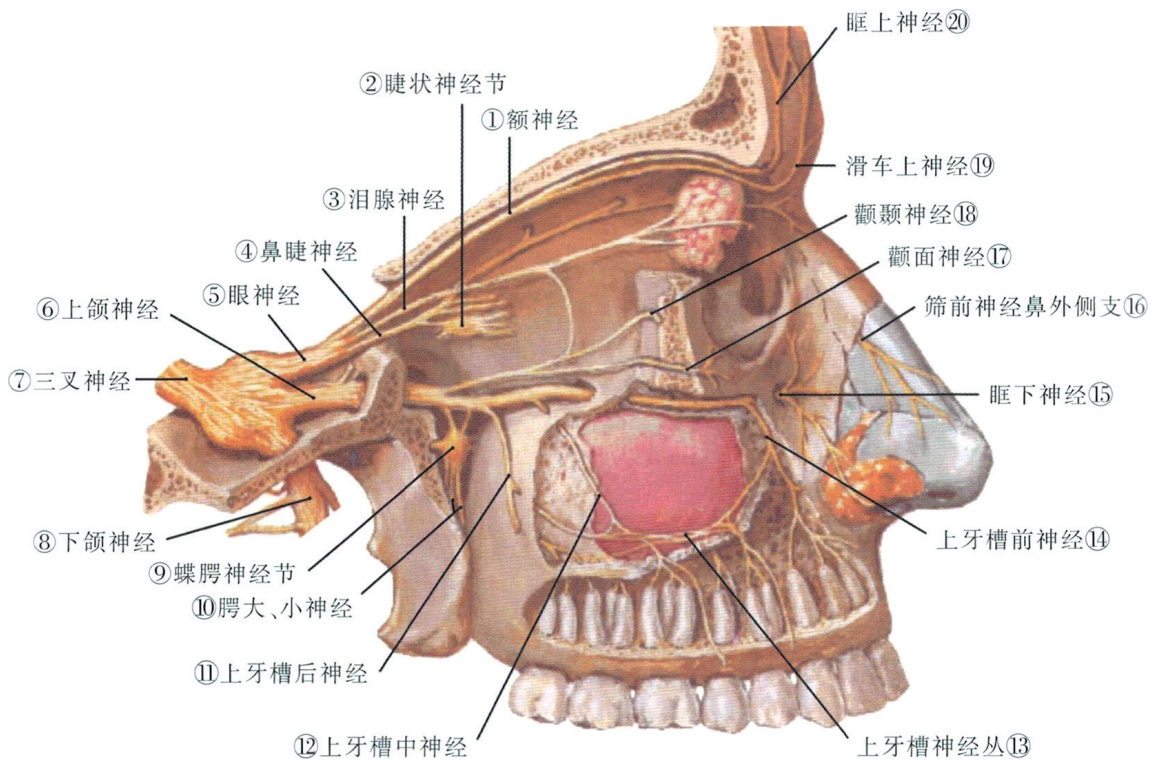
颌下腺及舌下腺内侧面观



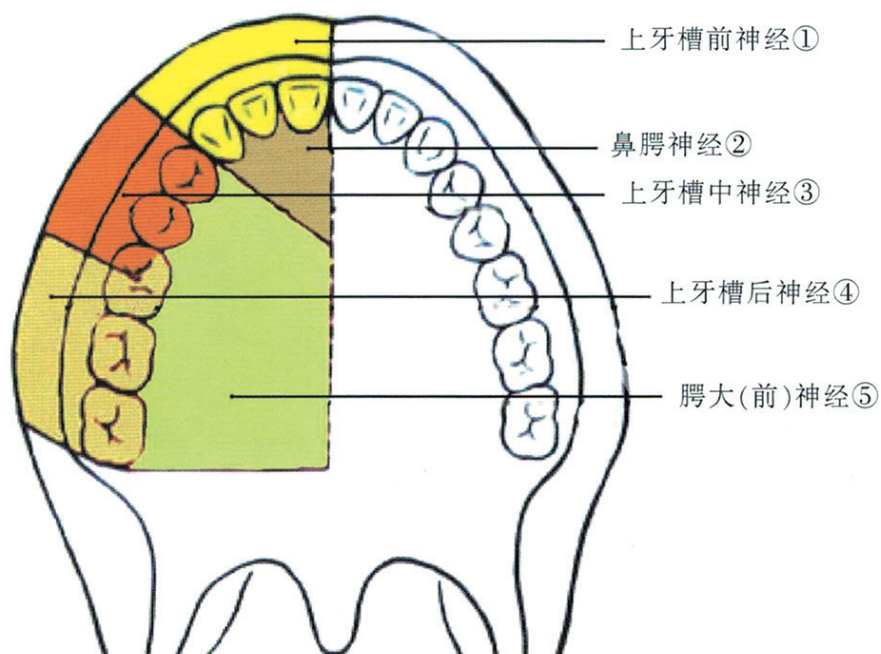
颈总动脉及锁骨下动脉的主要分支



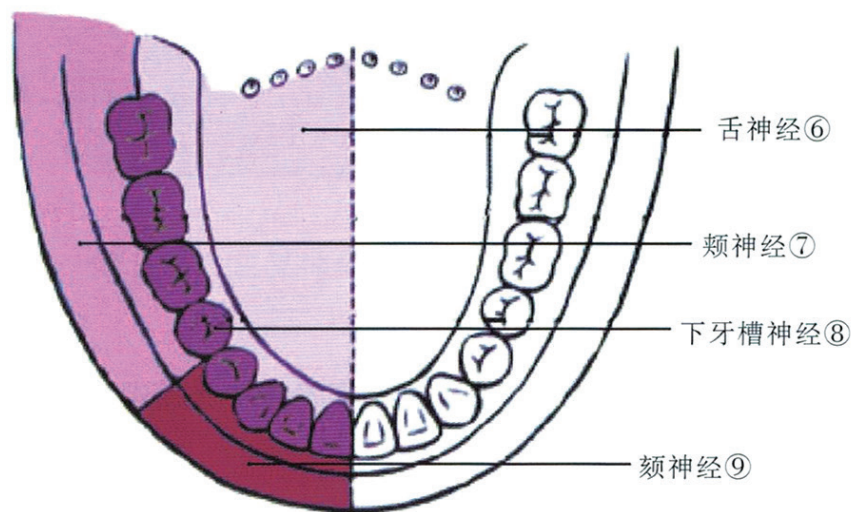
颌面颈部皮肤感觉神经分布示意图



眼神经及上颌神经外侧面观

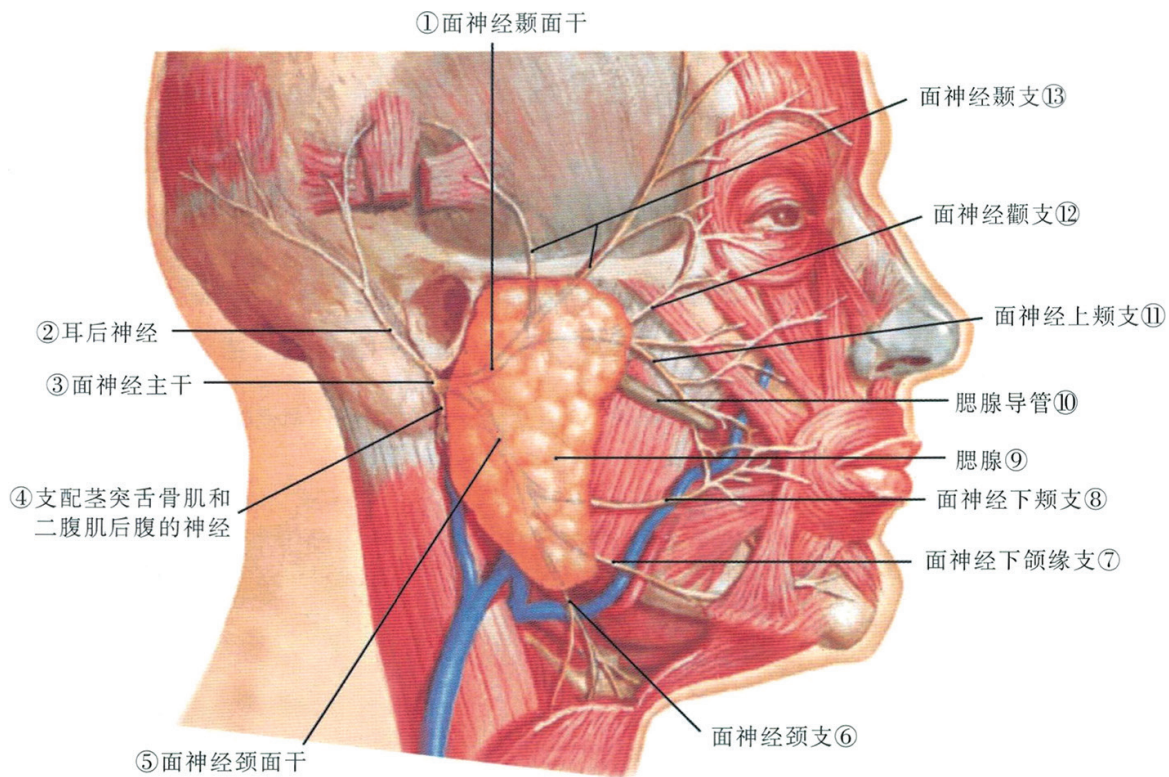


上 颌

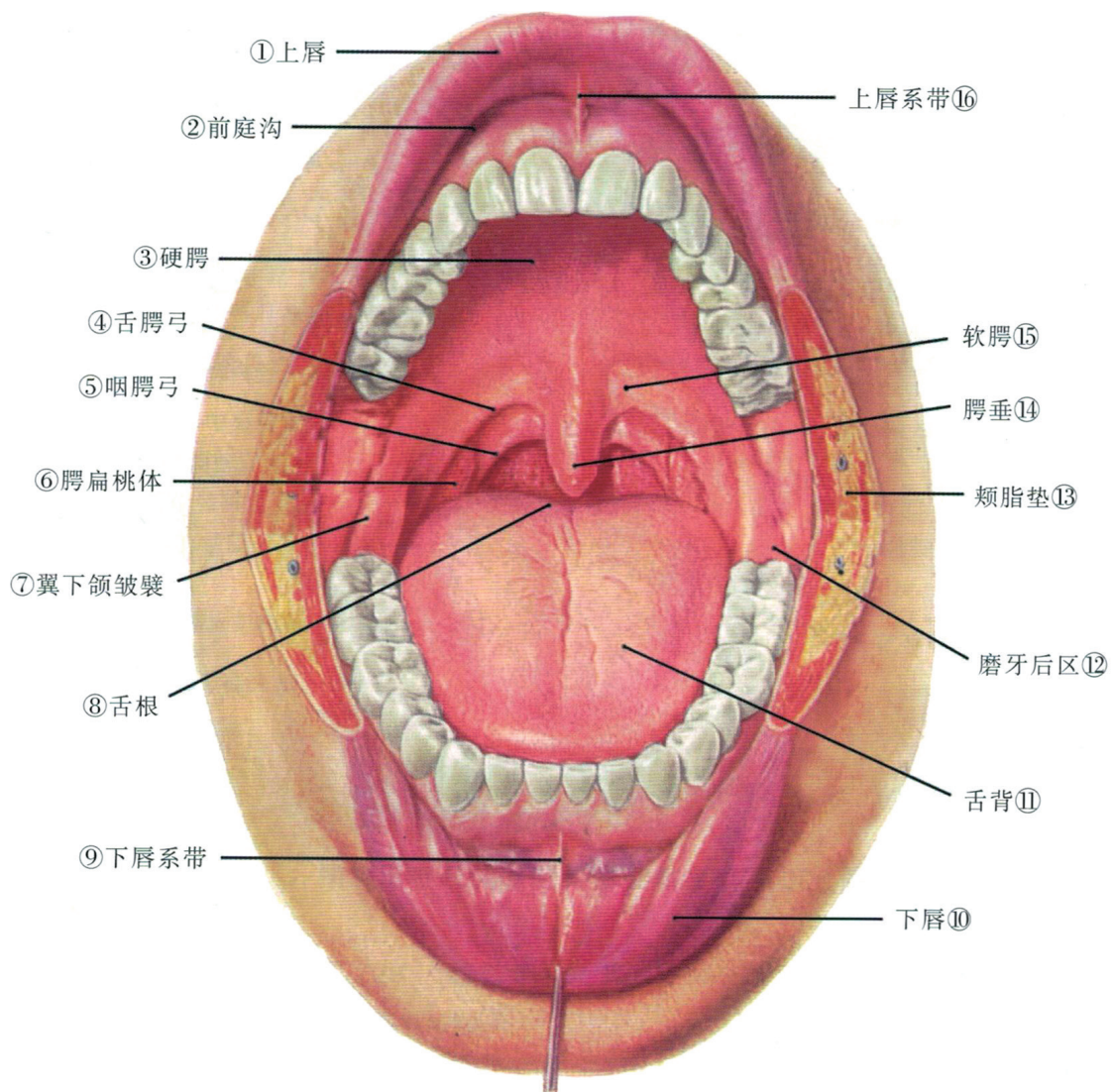


下 颌

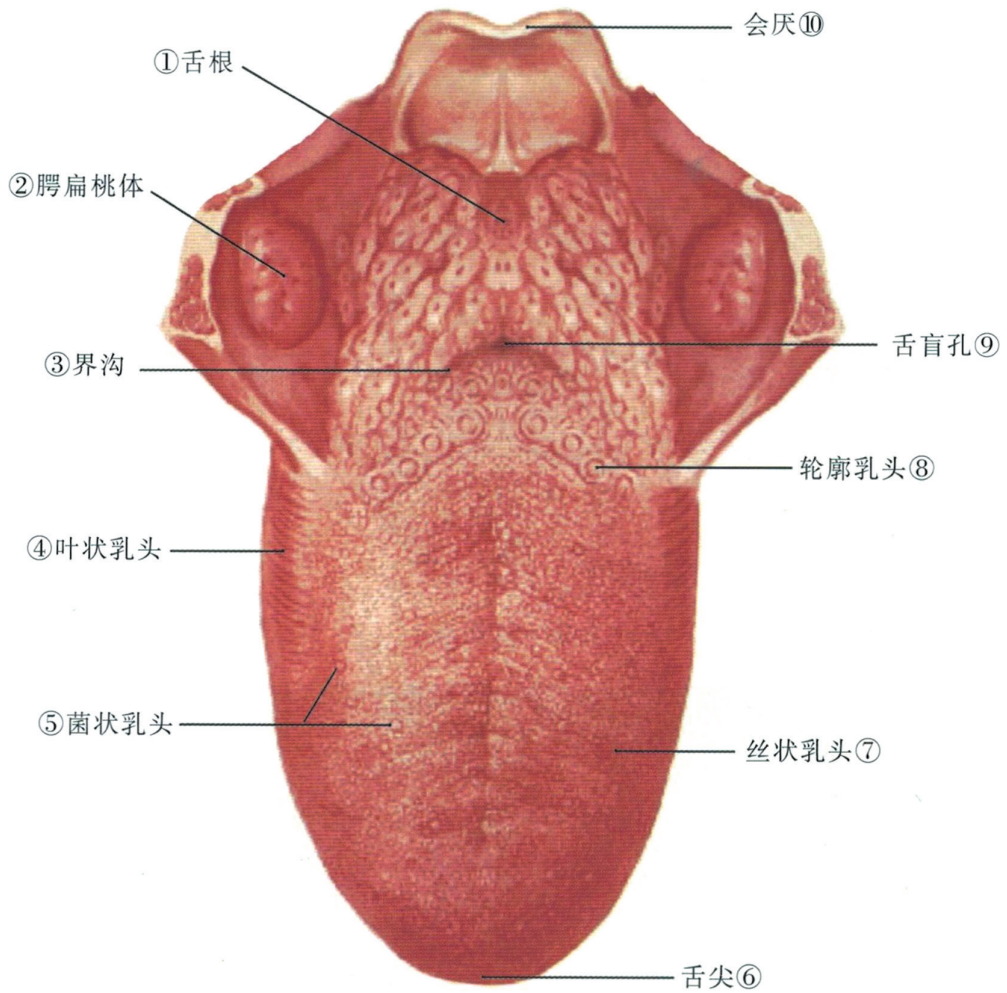
上下颌神经在口腔的分布



面神经分支及其与腮腺的关系



口腔前面观
口腔



舌背上面观